Deposition Diseases 48

Sven R. Quist, Jennifer E. Quist and Harald P. Gollnick

Chapter Contents

Gout 775
Pseudogout 778
Lipoid Proteinosis 778
Colloid Milium 780
Mucopolysaccharidoses 781

INTRODUCTION

The cutaneous deposition disorders are a heterogeneous group of conditions characterized by the presence of primarily endogenous substances within the dermis or the subcutis. Deposition disorders can be associated with localized or generalized cutaneous findings, and skin involvement is sometimes the earliest sign of a deposition disease. Histologic examination of cutaneous lesions, along with the use of special stains including immunohistochemistry, is a very helpful diagnostic tool (Table 48.1). In addition, specific enzymatic assays or genetic mutational analysis can then be performed to establish the precise diagnosis.

This chapter will focus on gout, pseudogout, lipoid proteinosis, colloid milium, and the mucopolysaccharidoses. Additional deposition disorders such as mucinoses, amyloidosis, porphyria, and calcinosis cutis are reviewed in Chapters 46–50.

GOUT

Synonyms ■ Urate crystal arthropathy ■ Podagra (first MTP joint) ■ Urate deposition disease

Key features

- Gout is a metabolic disease in which the underlying abnormality is hyperuricemia
- Deposits of needle-like crystals of monosodium urate are found in several sites, most commonly the skin (as tophi) and the joints
- In fresh preparations of synovial fluid and expressed material from tophi, the crystals exhibit negative birefringence when examined by polarized light
- In routinely fixed histologic sections, amorphous deposits that contain needle-like clefts are seen in the dermis and subcutis

Introduction

Gout is a metabolic disease in which needle-like crystals of monosodium urate (the ionized form of uric acid) from supersaturated fluids are deposited within tissue. Clinical manifestations include gouty arthritis, accumulation of crystals in connective tissue (tophi), uric acid nephrolithiasis, and renal impairment[1,2].

Epidemiology

Gout is the most common form of crystal-induced arthritis, and its prevalence seems to have increased over the past several decades. Men 40–50 years of age are most commonly affected. The male-to-female ratio is 9:1, and most women with gout are postmenopausal. Gout is found in up to 4% of adults and ~20% of patients have a family history of gout[2,3].

Pathogenesis

Gout is a consequence of deposits of urate crystals that have precipitated from supersaturated body fluids. Uric acid is the end product of the catabolism of purines. When the body increases its production of uric acid or if the kidneys do not excrete sufficient amounts, the result is hyperuricemia (Table 48.2). Migration and activation of neutrophils that are attempting to phagocytize urate crystals lead to the generation of neutrophil extracellular traps (NETs). The latter activate the NLRP3 inflammasome (see Fig. 4.2) via RIPK3-MLKL signaling, with subsequent production of proinflammatory cytokines. RIPK3 and MLKL represent two core proteins of the necroptosis pathway. Of note, NETs can also promote auto-resolution of the inflammatory phase of gout[4].

Clinical Features

The typical patient with gout is a middle-aged or older man, who may have a family history of the disease. Risk factors include obesity, excessive alcohol intake, renal insufficiency, and certain medications, most commonly diuretics. The natural history of gout involves four clinical stages[1]: (1) asymptomatic hyperuricemia; (2) acute gouty arthritis; (3) intercritical gout (the intervals between attacks, which progressively become shorter in duration); and (4) chronic tophaceous gout.

Acute gouty arthritis

The most common symptom of gout is the development of severe joint pain over a period of 6–12 hours, accompanied by tenderness, erythema, warmth, and swelling. Initial attacks are often monoarticular, but in up to 40% of patients they may be polyarticular[5]. In 75% of patients, the first metatarsophalangeal joint is involved (referred to as podagra); additional sites include the knee, ankle, and foot, and less commonly, the hand, wrist, and elbow. Fever and systemic symptoms may accompany an acute attack of gout. As the swelling subsides, the skin acquires a violaceous hue often followed by desquamation as edema subsides.

Chronic tophaceous gout

Cutaneous deposits of monosodium urate, known as "tophi", usually appear an average of 10 years after the onset of gout. These tophi present as firm dermal or subcutaneous papules and nodules or as a fusiform swelling. Their contours may be smooth or multilobulated (Fig. 48.1) and they vary from skin-colored to white–yellow to red (Fig. 48.2). The surface may be ulcerated and there may be associated drainage of material, which varies from clear fluid with white flecks to a thick chalky material.

The most common locations for tophi are the skin overlying joints and the helix of the ear. Unusual sites include the eyes, nose, larynx, breast, and heart valves. However, tophi develop in fewer than 10% of patients with gout. Depending upon the size and location of the tophi, complete, partial, or minimal resolution can occur when the serum uric acid level is normalized[2,6].

Elevated levels of uric acid in the urine are associated with uric acid nephrolithiasis and may cause acute renal failure when uric acid precipitates in the renal tubules and collecting ducts. The most common setting for the latter is tumor lysis syndrome following chemotherapy for a rapidly dividing chemosensitive malignancy, e.g. leukemias, lymphomas.

The initial diagnosis of gout is usually made in the setting of acute arthritis, based upon the presence of urate crystals in an aspirate of joint fluid. Hyperuricemia is usually present, but alone it is insufficient for establishing a definitive diagnosis of gout. Additional laboratory abnormalities during an acute attack include elevated white blood cell count (in the joint fluid and blood) and ESR.

Downloaded for Anonymous User (n/a) at Egyptian Knowledge Bank from ClinicalKey.com by Elsevier on March 10, 2024. For personal use only. No other uses without permission. Copyright ©2024. Elsevier Inc. All rights reserved.

DISORDERS WITH DERMAL DEPOSITS – HISTOLOGIC FEATURES			
Disease	**Microscopic findings**	**Histochemical stains**	**Special processing**
Gout	In formalin-fixed specimens, dermal deposits of amorphous material with needle-like clefts surrounded by a granulomatous infiltrate with giant cells Polarizing light/fresh preparation – fine, needle-like crystals; negative birefringence	20% silver nitrate solution: urate crystals appear black and the surrounding tissue yellow De Galantha stain: crystals brown–black	Best fixative to preserve crystals: ethanol-based (Carnoy's fluid)
Lipoid proteinosis	Masses of amorphous or laminated hyalin-like material Also surrounds capillaries in the papillary dermis and appendages	Contains type IV collagen and laminin PAS-positive and diastase-resistant ⊕ Alcian blue, hyaluronidase-sensitive Sudan III (+/–) Congo red (usually –)	Direct immunofluorescence with anti-ECM1 antibodies to assess protein expression
Colloid milium (adult form)	Nodules of amorphous eosinophilic material Artifactual clefts Solar elastosis	Stains similarly to amyloid (especially in frozen sections): ⊕ Congo red ⊕ Thioflavin T ⊕ Crystal violet	
Mucopolysaccharidoses	Metachromatic granules within fibroblasts Large vacuolated cells in sweat glands and the external root sheath of hair follicles (gargoyle cells)	Granules within fibroblasts: ⊕ Metachromasia with toluidine blue and Giemsa ⊕ Alcian blue ⊕ Colloidal iron (see Table 46.1)	Fixation in absolute alcohol better than in formalin (consider when clinical diagnosis not supported by histologic findings)
Mucinoses, e.g. papular mucinosis, scleredema, pretibial myxedema (Ch. 46)	Mucin between collagen and variable fibroblast proliferation	⊕ Metachromasia with toluidine blue ⊕ Alcian blue ⊕ Colloidal iron (see Table 46.1)	Fixation in absolute alcohol better than in formalin
Amyloidosis (Ch. 47)	Fractured, amorphous, faintly eosinophilic material in dermis	⊕ Congo red ⊕ Thioflavin T ⊕ Crystal violet	In glutaraldehyde for electron microscopy
Ochronosis (Chs. 63 & 67)	Sausage- or banana-shaped brown/yellow/orange structures	Black staining with methylene blue or cresyl violet	
Calcinosis cutis (Ch. 50)	Irregular masses of deeply basophilic materialVariable granulomatous inflammation (may be absent)	⊕ von Kossa ⊕ Alizarin red (more specific)	May fracture microtome blade May need decalcification solution first
Porphyrias, in particular EPP (Ch. 49)	Perivascular rim of delicate eosinophilic fibrillar material In chronic lesions, also dense homogeneous deposits	PAS-positive and diastase-resistant Immunohistochemistry for BMZ components (type IV collagen)	

Table 48.1 Disorders with dermal deposits – histologic features. BMZ, basement membrane zone; ECM1, extracellular matrix protein 1; EPP, erythropoietic protoporphyria.

CLASSIFICATION OF HYPERURICEMIA	
Overproduction of uric acid	• Primary/idiopathic • Excessive dietary purine intake and obesity • Increased nucleotide turnover • High-grade lymphomas (e.g. Burkitt) and myeloma • Myeloproliferative disorders, esp. acute myelogenous leukemia • Tumor lysis syndrome • Hemolysis • Psoriasis (severe) • Accelerated ATP degradation • Alcohol abuse • Severe muscle exertion • Hypoxanthine–guanine phosphoribosyl transferase deficiency (Lesch–Nyhan syndrome) • Glucose-6-phosphatase deficiency (glycogen storage disease type 1; von Gierke disease) • Phosphoribosyl pyrophosphatase synthetase overactivity
Decreased excretion of uric acid	• Primary/idiopathic • Chronic kidney disease • Enhanced tubular urate reabsorption (e.g. diuretics, dehydration) • Drug ingestion (e.g. cyclosporine > tacrolimus, pyrazinamide, low-dose salicylates) • Toxins (e.g. lead-induced nephropathy) • Miscellaneous – lactic acidosis, ketoacidosis, hypertension, hyperparathyroidism, hypothyroidism

Table 48.2 Classification of hyperuricemia. ATP, adenosine triphosphate.

Fig. 48.1 Tophaceous gout of a digit. The deposits create a multilobulated appearance and there is evidence of transepidermal elimination. A small incision over the yellow–white papules followed by microscopic examination of the expressed material would allow for a bedside diagnosis. *Courtesy Lorenzo Cerroni, MD.*

Downloaded for Anonymous User (n/a) at Egyptian Knowledge Bank from ClinicalKey.com by Elsevier on March 10, 2024. For personal use only. No other uses without permission. Copyright ©2024. Elsevier Inc. All rights reserved.

Fig. 48.2 Tophaceous gout of the tragus. The erythema reflects surrounding inflammation.

When examined by polarized light microscopy, the needle-shaped urate crystals change color from yellow to blue based upon their alignment relative to the axis of the "red plate" compensator, i.e. they exhibit negative birefringence. In patients with recurrent attacks, radiographs of involved joints often show "punched-out" erosions with sclerotic "overhanging" margins, but no osteophytes. A 24-hour urine collection for uric acid allows the identification of patients at risk for nephrolithiasis (see Table 48.2).

Pathology

The key histologic feature of formalin-fixed gouty tophi is the presence of deposits of amorphous material within the dermis and subcutis, corresponding to sites of crystal deposition. These deposits contain needle-like clefts (which represent dissolved urate crystals) surrounded by a granulomatous infiltrate with multinucleated giant cells (Fig. 48.3). Secondary calcification or even ossification can occasionally be seen in older lesions.

In order to preserve the crystals, the biopsy specimen needs to be placed in an ethanol-based fixative, such as Carnoy's fluid. Then, under regular or polarized light, brightly refractile brown sheaths of fine needle-like crystals can be seen. Upon staining with 20% silver nitrate solution, the crystals appear black and the surrounding tissue yellow, whereas with the De Galantha stain, the crystals appear brown to black[7].

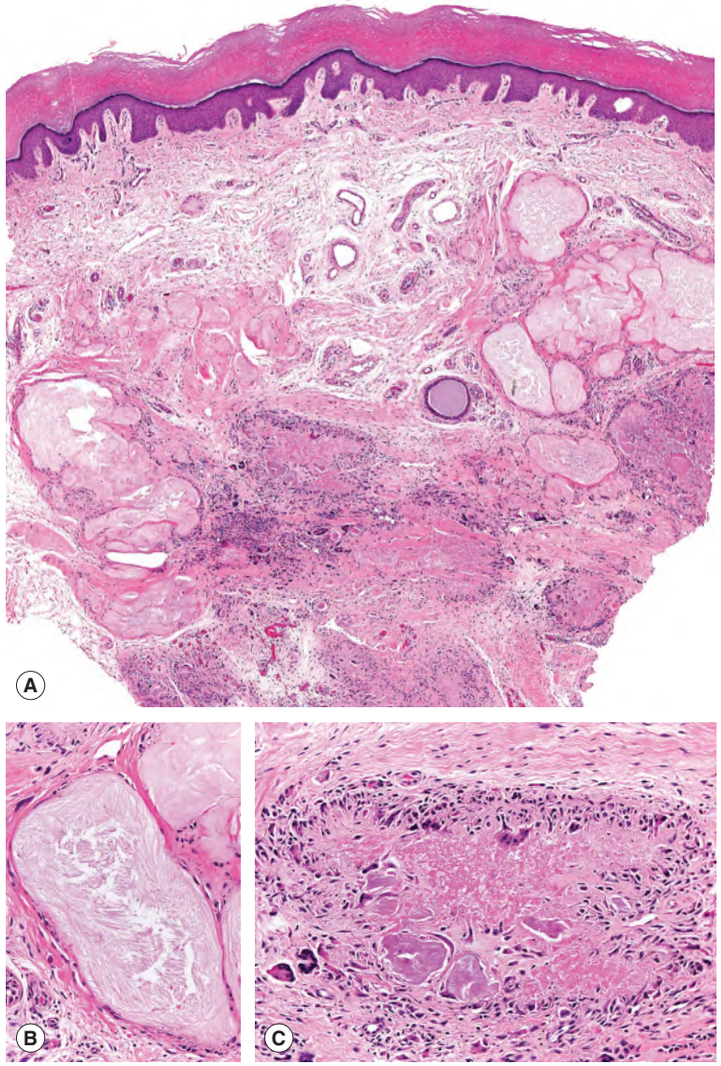

Fig. 48.3 Tophaceous gout – histopathologic features. A Within the dermis and subcutis, there are deposits of amorphous, acellular material. These deposits contain needle-like clefts (**B**). Histiocytes and multinucleated giant cells surround some of the deposits (**C**). *Courtesy Lorenzo Cerroni, MD.*

Differential Diagnosis

The differential diagnosis of acute gouty arthritis includes pseudogout (see below), osteoarthritis, psoriatic arthritis, reactive arthritis (previously referred to as Reiter disease), and septic arthritis. Given its destructive nature, septic arthritis needs to be considered even in patients in whom the diagnosis of gout has been previously established. The presence of needle-shaped crystals with negative birefringence in an aspirate of joint fluid is diagnostic of gout, while Gram stain and culture exclude septic arthritis. Occasionally, patients are misdiagnosed as having cellulitis.

The differential diagnosis of cutaneous gouty tophi includes xanthomas, rheumatoid nodules, and calcinosis cutis. Examination of expressed fluid or chalky material by polarized light can provide a "bedside" diagnosis. By ultrasonography, central clear spaces are seen within tophi whereas rheumatoid nodules contain central echodense areas[6].

Treatment

For acute gout, short-acting oral nonsteroidal anti-inflammatory drugs (NSAIDs) are taken within 24 hours of onset at the highest safe dosage as long as symptoms persist, e.g. indomethacin 50 mg three times daily for several days. Contraindications include peptic ulceration, renal insufficiency, and anticoagulation[6–8].

Colchicine, a derivative of the autumn crocus, inhibits the transport of phagocytized urate crystals to lysosomes within neutrophils via its binding to microtubules. Colchicine also interferes with leukocyte migration, chemotaxis, and adhesion. For patients with normal renal function who are not receiving strong CYP3A4 inhibitors, the recommended dosage for acute gout flares is 1.2 mg orally followed by 0.6 mg 1 hour later. Low-dose NSAIDs and colchicine (0.6 mg twice daily) are both utilized for prophylaxis. Outside of the US, colchicine tablets often contain 0.5 mg. Side effects of colchicine are outlined in Table 130.9. Intra-articular or systemic *corticosteroids* may be used for a period of 1–3 weeks if NSAIDs and colchicine are ineffective or contraindicated[6–8].

Urate-lowering therapy (ULT) consists of the xanthine oxidase inhibitors *allopurinol* and *febuxostat* which block uric acid production. Allopurinol is the preferred first-line ULT, but low starting doses (≤100 mg/day or lower if chronic kidney disease) are recommended[7]. ULT is indicated for patients with tophaceous gout, radiographic damage due to gout, or frequent gout flares. Concomitant anti-inflammatory prophylaxis therapy for 3–6 months is also recommended when initiating ULT[7].

Side effects of allopurinol include diarrhea, thrombocytopenia, hepatitis, and skin eruptions that can range from morbilliform to erythroderma to Stevens–Johnson syndrome/toxic epidermal necrolysis (SJS/TEN). HLA-B*58:01-positive individuals are at markedly increased risk of developing severe cutaneous adverse reactions, including both SJS/TEN and DRESS. Of note, this allele

Downloaded for Anonymous User (n/a) at Egyptian Knowledge Bank from ClinicalKey.com by Elsevier on March 10, 2024. For personal use only. No other uses without permission. Copyright ©2024. Elsevier Inc. All rights reserved.

is most common in those of Han Chinese, Korean, or Thai descent. Major side effects of febuxostat are liver enzyme elevations and cardiovascular thromboembolic events[9]. Drug–drug interactions, e.g. with azathioprine, can occur with both of these medications (see Fig. 130.5). Uricosuric agents such as oral *probenecid* can be added or used as second-line therapy for patients with normal renal function and no renal stones. Overall, maintenance of a serum uric acid level of ≤6 mg/dl is recommended. A newer agent, *lesinurad*, is a selective inhibitor of reabsorption of uric acid.

Some patients may benefit from a reduction in purine-rich foods (e.g. organ meats [liver, heart], fish), alcohol consumption, and body weight[6]. In the setting of potential tumor lysis syndrome, intravenous *rasburicase* can be administered, which rapidly converts uric acid to the more soluble allantoin. Bimonthly intravenous *pegloticase*, which has the same mechanism of action, can be used for patients with chronic gout refractory to conventional therapy. IL-1 blocking agents (e.g. *anakinra, canakinumab*) have been used for recurrent acute gout unresponsive to other therapies, but are not currently approved for this indication (see Fig. 45.13).

PSEUDOGOUT

Synonyms: ▪ Chondrocalcinosis ▪ Calcium pyrophosphate disease ▪ Calcium gout

Key features

- Pseudogout is a form of arthritis that is due to deposits of calcium pyrophosphate dihydrate (CPPD) crystals within the joint
- It most commonly affects the knee and other large joints of older persons with osteoarthritis
- In aspirates of joint fluid, there are rhomboid CPPD crystals that exhibit weakly positive birefringence under polarized light

Pseudogout, which may be clinically indistinguishable from gout, was recognized as a distinct disease entity in 1962[10]. It results when CPPD crystals (produced by nucleoside triphosphate pyrophosphohydrolase, a catalytic enzyme found in osteoarthritic cartilage) form within joint fluid and then lead to lysis of neutrophils that have ingested the crystals. As in gout, the formation of NETs plays a role in the inflammatory cascade. Although pseudogout is most commonly related to osteoarthritis, it has also been associated with metabolic abnormalities such as hyperparathyroidism and hemochromatosis.

Symptoms of pseudogout include intermittent attacks of pain and swelling of affected joints, most commonly the knee, wrist, and shoulder. The onset of symptoms in pseudogout is usually more insidious than in gout. Occasionally, extra-articular CPPD deposition (tophaceous pseudogout) may present as a hard subcutaneous nodule overlying joints, primarily of the head (especially the temporomandibular joint), neck, or distal extremities[11].

Microscopically, CPPD crystals appear shorter than urate crystals and are often rhomboidal in shape. In tophaceous pseudogout, rhomboid crystals as well as foci of calcification can be seen within the dermis. Polarizing microscopy of sections stained with a non-aqueous alcoholic eosin stain (NAES) allows the demonstration of CPPD crystals with positive birefringence[12]. This is in contrast to the negative birefringence of urate crystals in gout and the lack of birefringence of calcium hydroxyapatite crystals in tumoral calcinosis. Treatment of the acute phase of pseudogout is identical to that of gout[11]. In patients with chronic renal failure, the anti-IL-1β antibody *canakinumab* may be considered (see Fig. 45.13)[13].

LIPOID PROTEINOSIS

Synonyms: ▪ Hyalinosis cutis et mucosae ▪ Urbach–Wiethe disease

Key features

- A rare autosomal recessive deposition disorder due to mutations in *ECM1*, which encodes extracellular matrix protein 1
- Hyalin-like material is deposited within multiple organs, including the skin, oral mucosa, larynx, and brain
- Papules and nodules favor the face, as do pitted scars; diffuse waxy thickening of the skin can be associated with verrucous changes, especially on the elbows, knees, and hands

History

Lipoid proteinosis was first described by Siebenmann in 1908. Twenty years later, it was established as a distinct entity by two Viennese physicians, Erich Urbach, a dermatologist, and Camillo Wiethe, an otorhinolaryngologist.

Epidemiology

Most patients are of European ancestry, including descendants of Dutch immigrants who settled in South Africa in the middle of the 17th century[14]. Not only do Afrikaners have the highest incidence of this genetic disease, they also exhibit a founder effect, i.e. the population shares a common mutation.

Pathogenesis

In 2002, lipoid proteinosis was shown to be due to loss-of-function mutations in *ECM1*, which encodes extracellular matrix protein 1[15]. ECM1 is a secretory glycoprotein that can act as a negative regulator of endochondral bone formation, a promoter of angiogenesis, and an inhibitor of matrix metalloproteinase 9. In addition, ECM1a (see below) is found within the basement membrane zone and can enhance the binding of collagen IV to laminin 332. It also interacts with components of the extracellular matrix such as fibronectin and glycosaminoglycans (e.g. hyaluronic acid, chondroitin sulfate)[16].

ECM1 has three major splice variants that result in different isoforms: (1) ECM1a, a protein of 540 amino acids encoded by a 10-exon gene; (2) ECM1b, a protein of 415 amino acids reflecting a lack of exon 7; and (3) ECM1c, a protein of 559 amino acids due to an additional exon 5a within intron 5. Patients with mutations in exon 7 still express the ECM1b isoform and tend to have milder disease as compared to those with mutations in exon 6, who tend to have more severe disease and reduced expression of all three isoforms. A majority of pathogenic mutations occur within exon 6 or 7[15]; occasionally, they occur in exon 2, 4, or 9[17]. The degree of dermal immunofluorescent staining (utilizing an anti-ECM1 antibody) points to the location; reduced staining suggests mutations in exon 7 and an absence of staining mutations in exon 6[16].

Clinical Features

The first clinical sign of lipoid proteinosis is often a weak cry or hoarseness due to infiltration of the laryngeal mucosa. Hoarseness remains throughout life. Cutaneous lesions usually appear during the first 2 years of life, in two overlapping stages. In the first stage, vesicles and hemorrhagic crusts develop within the mouth and on the skin of the face and extremities, often in association with trauma. The cutaneous lesions may resolve with scarring, including "ice-pick"-like scars.

During the second stage, there is an increase in the hyalin deposits within the dermis (Fig. 48.4). The skin becomes diffusely thickened and waxy and develops a yellow color. Papules, plaques, and nodules appear on the face (including the eyelid margin) as well as in the axillae and on the scrotum. Verrucous lesions may develop on the extensor surfaces, especially the elbows (see Fig. 48.4C), knees, and hands. Generalized scaling has also been observed as has alopecia of the eyebrows and eyelashes. Corneal ulcers may occur due to infiltration of the eyelids.

Downloaded for Anonymous User (n/a) at Egyptian Knowledge Bank from ClinicalKey.com by Elsevier on March 10, 2024. For personal use only. No other uses without permission. Copyright ©2024. Elsevier Inc. All rights reserved.

Fig. 48.4 Lipoid proteinosis – clinical features. A Beaded eyelid papules (moniliform blepharosis), hemorrhagic crusts, and confluent waxy papules of the glabella leading to an early leonine facies. **B** Skin-colored papulonodules of the elbow as well as irregular hypopigmented scars of the extensor forearm. **C** Characteristic verrucous changes of the elbow. **D** A firm tongue with numerous tiny papules on the dorsal surface. **E** Multiple, round hypopigmented and depressed scars on the shoulder. **F** Waxy, yellowish plaque on the back. *B, D, E, Courtesy Julie V. Schaffer, MD; C, Courtesy Judit Stenn, MD.*

In addition to involvement of the tongue (diffuse infiltration), the frenulum (restricted motion of the tongue), and the oropharynx, recurrent parotitis can occur due to occlusion of the salivary duct. Dental anomalies include hyperplasia or aplasia of the upper incisors, premolars or molars; patients usually lose their teeth at an early age. Neurologic manifestations are common and consist of behavioral and learning difficulties, seizures, and, less often, intracerebral hemorrhage. A pathognomonic radiographic finding is bilateral, intracranial, sickle-shaped calcification within the amygdalae[18]. More recently, an increased prevalence of renal cysts has been described.

In general, the disease has a stable or slowly progressive course that is compatible with a normal lifespan, except for the risk of respiratory obstruction in infancy. An elevated ESR may be seen due to increased α- or γ-globulins.

Pathology

The major clinical manifestations are related to the deposition of an amorphous or laminated material around blood vessels and within the connective tissues. The amorphous deposits consist primarily of non-collagen proteins, while the concentric layers of basement membrane-like material contain collagen (types II and IV) and laminin. In addition, the deposits are PAS-positive and diastase-resistant, indicating the presence of neutral glycosaminoglycans (GAGs; mucopolysaccharides).

Downloaded for Anonymous User (n/a) at Egyptian Knowledge Bank from ClinicalKey.com by Elsevier on March 10, 2024. For personal use only. No other uses without permission. Copyright ©2024. Elsevier Inc. All rights reserved.

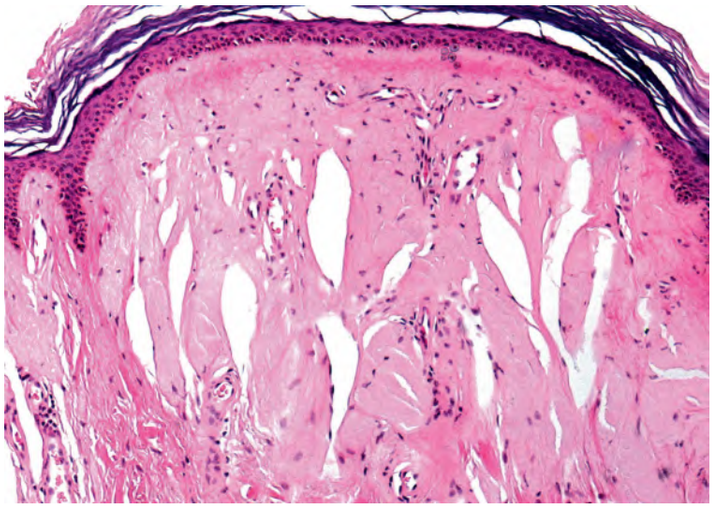

Fig. 48.5 Lipoid proteinosis – histopathologic features. Hyperkeratosis, a flattened epidermis, and vertically oriented eosinophilic deposits in the dermis. Note the cleft formation. *Courtesy Lorenzo Cerroni, MD.*

H&E-stained sections of early lesions reveal pink, hyalin-like deposits around the capillaries within the papillary dermis and at the periphery of eccrine sweat glands. Older lesions are characterized by hyperkeratosis, occasionally papillomatosis, and a thickened dermis in which bundles of pink hyalin deposits are found in a diffuse pattern (Fig. 48.5); the bundles are often oriented perpendicularly to the dermal–epidermal junction. There are smaller scattered deposits of hyalin in the lower dermis. Hyalin deposits also surround the hair follicles, sebaceous glands, and arrector pili muscles as well as the eccrine glands.

In addition to type IV collagen, laminin, and neutral GAGs, hyaluronic acid is present in the dermis, as demonstrated by Alcian blue and hyaluronidase staining (see Ch. 46). Fat stains (e.g. Sudan III) give inconsistent results when the tissue is formalin-fixed, and rarely the deposits stain with Congo red. Ultrastructurally, reduplication of the basement membrane of vessels and occasionally the dermal–epidermal junction is seen; the deposits appear to be composed of small granules and short filaments of low electron density that measure 3–5 nm in diameter.

There are few reports of the histopathologic features of the vesicular first phase and they vary from intraepidermal acantholysis to cell-poor subepidermal blisters.

Differential Diagnosis

The clinical differential diagnosis includes erythropoietic protoporphyria (EPP), amyloidosis, papular mucinosis (scleromyxedema), colloid milium, and non-Langerhans cell histiocytoses. During the initial phase, hydroa vacciniforme may be considered. In infants, the possibility of hyaline fibromatosis syndrome (juvenile hyaline fibromatosis and infantile systemic hyalinosis) needs to be considered, which is due to mutations in the gene that encodes capillary morphogenesis protein 2 (see Ch. 98). Histologically, the differential diagnosis includes EPP and colloid milium. In cutaneous lesions of EPP, colloid milium, and amyloidosis (see Table 48.1), the hyalinization is milder, more focal and superficial, and it rarely involves the eccrine glands. The deposits in colloid milium do not have the striking perivascular pattern seen in lipoid proteinosis.

Treatment

Currently, there is no known cure or effective treatment for lipoid proteinosis. Oral, intralesional (including submucosal), and topical corticosteroids have been used with some beneficial effect, as have humectants. Plastic surgery, dermabrasion, and laser resurfacing have been successfully performed[19], and there are limited reports of the use of systemic retinoids (e.g. acitretin 0.5 mg/kg/day for 6 months)[20], D-penicillamine, and oral dimethyl sulfoxide (DMSO)[21].

COLLOID MILIUM

Synonyms: ▪ Colloid degeneration of the skin ▪ Elastosis colloidalis conglomerata ▪ Miliary colloidoma

Key features

- A rare disorder in which dome-shaped, translucent papules develop in sun-exposed skin
- Four variants are recognized: adult, juvenile, and pigmented colloid milium and nodular colloid degeneration
- Histologically, amorphous, eosinophilic, granular deposits are found within the superficial dermis

Introduction and Epidemiology

Adult colloid milium is the most common form of the disease. It usually occurs in middle-aged, fair-skinned individuals who have had significant cumulative sun exposure, with a male-to-female ratio of 4 : 1. The adult form has also been observed in outdoor oil refinery workers, suggesting an additional effect of petrochemicals. In general, *juvenile* colloid milium develops before puberty and both an autosomal recessive and an autosomal dominant inheritance pattern have been reported[22].

Pathogenesis

Although excessive sun exposure clearly plays a role in *adult* colloid milium, the precise pathogenesis is not known. Photoinduced damage to dermal elastic fibers, as in solar elastosis, has been suggested. In *juvenile* colloid milium, ultraviolet light-induced damage to epidermal keratinocytes has been observed and this may reflect an inherited susceptibility. *Pigmented* colloid milium is a variant of the adult form in which there is a combination of excessive sun exposure plus topical application of hydroquinone or phenols[23].

Clinical Features

In both the *adult and juvenile* forms, multiple, dome-shaped, translucent to yellow or yellow–brown papules are seen in areas of chronic sun exposure (Fig. 48.6), e.g. the face (especially periorbitally), ears, posterolateral neck, and the dorsal aspect of the hands and forearms. With minor trauma, lesions can become hemorrhagic. By dermoscopy, a diffuse orange background is seen along with linear-curved blurred telangiectasias and a few milia-like cysts. In *pigmented* colloid milium, grouped to confluent gray–brown papules are present on the face, whereas in *nodular colloid degeneration*, skin-colored to yellowish nodules or plaques develop, often on the face[22,23].

Pathology

In *adult* colloid milium, nodules composed of homogeneous eosinophilic colloid material are seen in the papillary dermis (Fig. 48.7). Within the nodules, there may be clefts and fissures. A grenz zone is often present, as is evidence of solar elastosis beneath the nodules. Although the colloid masses contain degenerated elastic fibers, they often exhibit a staining profile similar to amyloidosis, i.e. positive staining with crystal violet, Congo red, and thioflavin T stains; such staining is more consistent in frozen sections. In addition, PAS staining is positive. A negative pan-cytokeratin stain is helpful in distinguishing adult colloid milium from primary cutaneous amyloidosis (amyloid K).

In *juvenile* colloid milium, amorphous eosinophilic deposits are also found within the papillary dermis, but when compared to the adult form, there is less clefting and no grenz zone. As with colloid bodies (which are also keratinocyte-derived), nonspecific staining for immunoglobulins, complement, and fibrin is seen. Similar to primary cutaneous amyloidosis, staining for keratin is positive due to the presence of amyloid K.

In *pigmented* colloid milium, lightly pigmented islands of colloid material are found in the upper dermis. In *nodular colloid degeneration*,

Downloaded for Anonymous User (n/a) at Egyptian Knowledge Bank from ClinicalKey.com by Elsevier on March 10, 2024. For personal use only. No other uses without permission. Copyright ©2024. Elsevier Inc. All rights reserved.

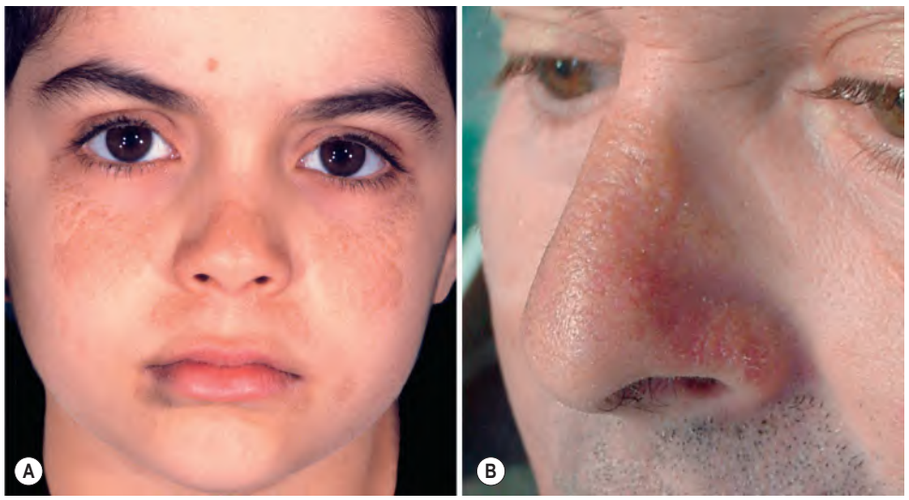

Fig. 48.6 Juvenile and adult colloid milium. A Coalescing brown papules in sun-exposed sites of the face. Note the sparing of the philtrum. **B** Yellowish, translucent papules and multi-lobulated plaques are present on the nose, admixed with telangiectasias. *A, Courtesy Lorenzo Cerroni, MD, and Sergio Chimenti, MD; B, Courtesy Luis Requena, MD.*

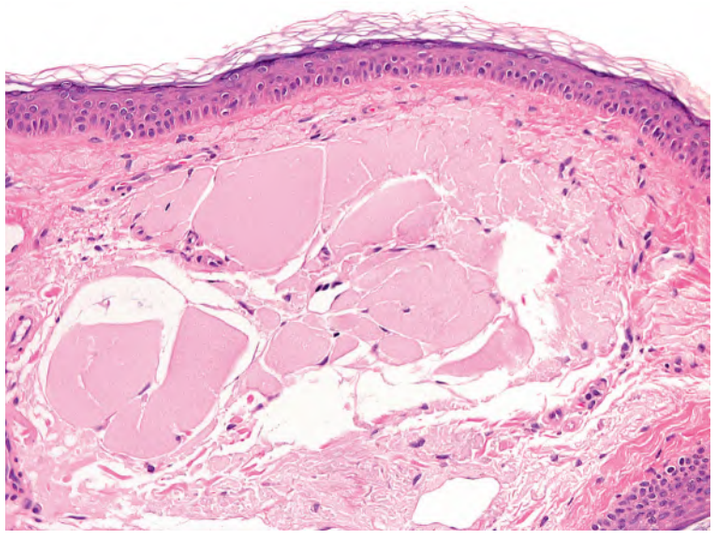

Fig. 48.7 Adult colloid milium – histopathologic features. Nodular mass of eosinophilic, homogeneous material within the upper dermis with a thin subepidermal grenz zone. Note fissures and clefts within the mass with a few fibroblasts along some of the clefts. *Courtesy Lorenzo Cerroni, MD.*

homogenized amorphous dermal collagen with small fissures and clefts is seen. Whether this entity is a variant of nodular amyloidosis is still under debate. Ultrastructurally, colloid milium is characterized by amorphous and granular material which lacks the straight, non-branching filaments seen in amyloidosis.

Differential Diagnosis

Clinically, the differential diagnosis of juvenile and adult forms of colloid milium includes erythropoietic protoporphyria (EPP), mucinoses (e.g. papular, self-healing), lipoid proteinosis, adnexal tumors, and primary systemic amyloidosis (adults). Pigmented colloid milium needs to be distinguished from exogenous ochronosis. Histologically, colloid milium must be distinguished from EPP, lipoid proteinosis, and primary cutaneous amyloidosis. In cutaneous lesions of EPP, there are hyalin deposits around and within the superficial blood vessel walls, whereas the dermal deposits of lipoid proteinosis are accentuated around the blood vessels. Primary cutaneous amyloidosis may be indistinguishable from the juvenile type of colloid milium, as both stain positively for keratin; some authors consider juvenile colloid milium to be a variant of lichen amyloidosis. Unlike lipoid proteinosis and lichen amyloidosis, the dermal deposits of adult colloid milium do not stain positively for laminin and type IV collagen or cytokeratin, respectively.

Treatment

Treatment modalities are limited and include laser therapy (e.g. long-pulsed Er:YAG, fractional photothermolysis), dermabrasion, intense pulsed light, photodynamic therapy, cryotherapy, and chemical peels[24].

MUCOPOLYSACCHARIDOSES

Key features

- A group of inherited disorders, primarily autosomal recessive, characterized by deficiencies of specific lysosomal enzymes involved in the catabolism of glycosaminoglycans (GAGs), also referred to as mucopolysaccharides
- Excessive amounts of the GAGs are found in various tissues and lead to coarse facies, intellectual disability, hepatosplenomegaly, skeletal abnormalities, and corneal clouding
- Hunter syndrome (X-linked recessive) has distinctive skin-colored to white papules over the scapulae (pebbling)
- Screening tests include examination of the urine, peripheral leukocytes, and dermal fibroblasts for the presence of excessive GAGs followed by genetic mutational analysis

Clinical Features and Pathology

The mucopolysaccharidoses are due to mutations in several genes that encode enzymes involved in the catabolism of glycosaminoglycans (GAGs)[25]. Examples of these GAGs include dermatan sulfate, heparan sulfate, and chondroitin sulfate. The storage of excessive amounts of GAGs in various tissues can lead to coarse facies, intellectual disability, hepatosplenomegaly, skeletal abnormalities (dysostosis multiplex), joint stiffness, cardiovascular disease, and corneal clouding (Table 48.3).

Cutaneous manifestations are nonspecific (e.g. hypertrichosis, thickening of the skin), except for the presence of skin-colored to white papules or nodules over the scapulae ("pebbling") in patients with Hunter syndrome[26], which is inherited in an X-linked recessive fashion. The lesions measure 1–10 mm in diameter and may become confluent; they can extend from the posterior axillary line to the midline. Less common sites are the arms, the lateral upper chest, and the buttocks. Extensive dermal melanocytosis (i.e. Mongolian spots) can occur on the trunk and extremities in patients with Hunter or Hurler syndrome.

Screening tests include examination of the urine for excessive amounts of GAGs and examination of circulating leukocytes or dermal fibroblasts for vacuoles or granules that can be demonstrated via special stains (see Table 46.1). The peripheral blood smear should be fixed in absolute methanol and fixation of the skin biopsy specimen in absolute alcohol is preferred. Specific enzyme assays or genetic mutational analysis can then be performed; prenatal diagnosis is possible.

Downloaded for Anonymous User (n/a) at Egyptian Knowledge Bank from ClinicalKey.com by Elsevier on March 10, 2024. For personal use only. No other uses without permission. Copyright ©2024. Elsevier Inc. All rights reserved.

THE MUCOPOLYSACCHARIDOSES				
Disorder	**Enzyme deficiency**	**Stored material**	**Clinical types (onset)**	**Inheritance**
MPS 1 H, Hurler	α-L-Iduronidase	Dermatan sulfate Heparan sulfate	Infancy	AR
MPS I H/S, Hurler/Scheie	α-L-Iduronidase	Dermatan sulfate Heparan sulfate	Childhood	AR
MPS I S, Scheie	α-L-Iduronidase	Dermatan sulfate Heparan sulfate	Late childhood/early adulthood	AR
MPS II, Hunter	Iduronate 2-sulfatase	Dermatan sulfate Heparan sulfate	Severe – infancy Mild – late childhood	X-linked recessive
MPS III A–D, Sanfilippo A–D	A: Heparan-*N*-sulfatase B: *N*-acetyl-α-glucosaminidase C: Acetyl-CoA: α-glucosaminide *N*-acetyltransferase D: *N*-acetyl-glucosamine-6-sulfatase	Heparan sulfate	Early childhood	AR
MPS IV A, Morquio A	*N*-acetylgalactosamine-6-sulfatase	Keratan sulfate Chondroitin-6 sulfate	Childhood	AR
MPS IV B, Morquio B	β-Galactosidase†	Keratan sulfate Chondroitin-6 sulfate	Childhood	AR
MPS VI, Maroteaux–Lamy	Arylsulfatase B (*N*-acetylgalactosamine-4-sulfatase)	Dermatan sulfate	Late infancy/childhood	AR
MPS VII, Sly	β-Glucuronidase	Dermatan sulfate Heparan sulfate Chondroitin-4 and -6 sulfate	Wide range Severe – neonatal Mild – adolescence	AR

*Persistent and extensive, often involving the anterior as well as posterior trunk; has also been described in patients with GM1 gangliosidosis (see Ch. 63).
†Allelic with GM1 gangliosidosis.

Table 48.3 The mucopolysaccharidoses. AR, autosomal recessive; MPS, mucopolysaccharidosis. *Adapted with permission from Hopkin RJ, Grabowski GA. Lysosomal storage diseases. In: Kasper DL, Fauci AS, Hauser SL, et al (eds). Harrison's Principles of Internal Medicine, 19th edn. New York: McGraw-Hill, 2015.*

In biopsy specimens from all types of mucopolysaccharidosis (MPS), metachromatic granules are seen within the cytoplasm of fibroblasts and in some cases in sweat glands, the external root sheath of hair follicles, and epidermal keratinocytes. The latter may have a pale distended cytoplasm which displaces the nucleus to one side. Biopsy specimens of diffusely thickened skin demonstrate fragmentation and hyalinization of collagen and increased mucin. Extracellular deposits of metachromatic material and mucin deposition are seen in the papulonodular lesions of Hunter syndrome[26]. By electron microscopy, fibrillogranular material is seen within lysosomes in all types of MPS.

Treatment

Although supportive interventions (e.g. home oxygen, physical therapy for joint stiffness, cardiac valve replacement) play an important role in the treatment of MPSs, additional therapeutic options – in particular, enzyme replacement therapy (ERT) and hematopoietic stem cell transplantation (HSCT) offer long-term hope for affected individuals[27,28]. Currently available ERT includes α-L-iduronidase (laronidase; Aldurazyme™) for MPS I, iduronate-2-sulfatase (idursulfase; Elaprase™) for MPS II, *N*-acetylgalactosamine 4-sulfatase (galsulfase; Naglazyme™) for MPS VI, and β-glucuronidase (vestronidase-α; Mepsevii™) for MPS VII. ERT is effective in controlling pulmonary insufficiency, decreased joint mobility and hepatosplenomegaly, but does not improve bone or valvular heart disease. Nor does it affect the intellectual disability, as the enzymes cannot pass the blood–brain barrier[27].

Allogeneic HSCT has been used successfully in patients with MPS I, II, IVA, VI, and VII[28]. Results vary depending upon the age of the patient and the disease stage at the time of the procedure, with better results when performed at an early age. Joint mobility, cardiopulmonary function, hearing, vision, and coarse facies can be improved with allogeneic HSCT, in addition to improvement of CNS impairment in MPS I, II, and VII[28]. Substrate reduction therapy and gene therapy represent future treatment options[25,29]. An example of the latter is administration of hematopoietic stem and progenitor cells transduced *ex vivo* with an α-L-iduronidase-encoding lentiviral vector after myeloablative conditioning[29a].

Additional figures available in our eBook (see inside front cover for access code).

REFERENCES

1. Touart DM, Sau P. Cutaneous deposition diseases. Part II. *J Am Acad Dermatol*. 1998;39:527–544.
2. Richette P, Bardin T. Gout. *Lancet*. 2010;375:318–328.
3. Zhu Y, Pandya BJ, Choi HK. Prevalence of gout and hyperuricemia in the US general population: the National Health and Nutrition Examination Survey 2007–2008. *Arthritis Rheum*. 2011;63:3136–3141.
4. Garcia-Gonzales E, Gamberucci A, Lucherini OM, et al. Neutrophil extracellular traps release in gout and pseudogout depends on the number of crystals regardless of leukocyte count. *Rheumatology (Oxford)*. 2021;60:4920–4928.
5. Lawrence RC, Helmick CG, Arnett FC. Estimates of the prevalence of arthritis and selected musculoskeletal disorders in the United States. *Arthritis Rheum*. 1998;41:778–799.
6. Keith MP, Gilliland WR. Updates in the management of gout. *Am J Med*. 2007;120:221–224.
7. Fitzgerald JD, Dalbeth N, Mikuls T, et al. 2020 American College of Rheumatology Guidelines for the Management of Gout. *Arthritis Rheumatol*. 2020;72:879–895.
8. Zhang W, Doherty M, Bardin T, et al. EULAR evidence based recommendations for gout. Part II: management. Report of a task force of the EULAR Standing Committee for International Clinical Studies Including Therapeutics (ESCISIT). *Ann Rheum Dis*. 2006;65:1312–1324.
9. Becker MA, Schumacher Jr HR, Wortmann RL, et al. Febuxostat compared with allopurinol in patients with hyperuricemia and gout. *N Engl J Med*. 2005;353:2450–2461.
10. McCarty DJ, Kohn NN, Faire JS. The significance of calcium phosphate crystals in the synovial fluid of arthritic patients: the "pseudogout" syndrome. Clinical aspects. *Ann Intern Med*. 1962;56:711–737.

Downloaded for Anonymous User (n/a) at Egyptian Knowledge Bank from ClinicalKey.com by Elsevier on March 10, 2024. For personal use only. No other uses without permission. Copyright ©2024. Elsevier Inc. All rights reserved.

THE MUCOPOLYSACCHARIDOSES					
Clinical features					
Neurologic	**Liver and/or spleen enlargement**	**Skeletal disease**	**Ophthalmologic**	**Hematologic**	**Other features**
Intellectual disability	+++	++++	Corneal clouding	Vacuolated lymphocytes	Coarse facies, cardiovascular involvement, respiratory compromise, joint stiffness, dermal melanocytosis*
Mild intellectual disability	++	++	Corneal clouding	Vacuolated lymphocytes	Severity intermediate between Hurler and Scheie
None	+	+	Corneal clouding	Vacuolated lymphocytes	Normal stature, valvular heart disease, joint stiffness, carpal tunnel syndrome
Intellectual disability, less in mild form	++ to +++	++ to ++++	Retinal degeneration, no corneal clouding	Granulated lymphocytes	Coarse facies, cardiovascular involvement, joint stiffness, distinctive pebbly skin lesions, dermal melanocytosis*
Severe intellectual disability, with deterioration during early childhood	+	+	None	Granulated lymphocytes	Mild coarse facies, usually normal stature, severe behavioral problems
None	+	++++	Corneal clouding	Granulated neutrophils	Distinctive skeletal deformity, odontoid hypoplasia, aortic valve disease
None	±	++++	Corneal clouding	Granulated neutrophils	See above, Morquio A
None	++	++++	Corneal clouding	Granulated neutrophils and lymphocytes (most prominent of all MPS)	Coarse facies, valvular heart disease, upper airway obstruction
Intellectual disability, absent in some adults	+ to +++	+ to +++	Corneal clouding	Granulated neutrophils	Coarse facies, cardiovascular involvement, hydrops fetalis in neonatal form

11. Joseph J, McGrath H. Gout or "pseudogout": how to differentiate crystal-induced arthropathies. *Geriatrics*. 1995;50:33–39.
12. Shidham V, Chivukula M, Basir Z, Shidham G. Evaluation of crystals in formalin-fixed, paraffin-embedded tissue sections for the differential diagnosis of pseudogout, gout, and tumoral calcinosis. *Mod Pathol*. 2001;14:806–810.
13. Announ N, Palmer G, Guerne PA, Gabay C. Anakinra is a possible alternative in the treatment and prevention of acute attacks of pseudogout in end-stage renal failure. *Joint Bone Spine*. 2009;76:424–426.
14. Heyl T. Lipoid proteinosis in South Africa. *Dermatologica*. 1971;142:129–132.
15. Hamada T, McLean WH, Ramsay M, et al. Lipoid proteinosis maps to 1q21 and is caused by mutations in the extracellular matrix protein 1 gene (*ECM1*). *Hum Mol Genet*. 2002;11:833–840.
16. Sercu S, Zhang M, Oyama N, et al. Interaction of extracellular matrix protein 1 with extracellular matrix components: ECM1 is a basement membrane protein of the Skin. *J Invest Dermatol*. 2008;128:1397–1408.
17. Chelvan HT, Narasimhan M, Subramanian AS, Subramanian S. Lipoid proteinosis presenting with unusual nonsense Q32X mutation in exon 2 of the extracellular matrix protein 1 gene. *Australas J Dermatol*. 2012;53:e70–e82.
18. Arkadir D, Lerer I, Klapholz L, et al. Lipoid proteinosis with bilateral amygdalae calcifications, headache, and cognitive impairments. *Neurology*. 2013;81:303–304.
19. Buchan NG, Kemble JV. Successful surgical treatment of lipoid proteinosis. *Br J Dermatol*. 1974;90:561–566.
20. Dowlati A, Dowlati Y, Mansauri P. Lipoid proteinosis and its response to etretinate therapy. In: Pierard GE, Pierard-Franchimont C, eds. *The Dermis: From Biology to Diseases. Liège*. Belgium: Service de Dermatopathologie;; 1989:135–142.
21. Wong CK, Lin CS. Remarkable response of lipoid proteinosis to oral dimethyl sulphoxide. *Br J Dermatol*. 1988;119:541–544.
22. Lewis AT, Le EH, Quan LT, et al. Unilateral colloid milium of the arm. *J Am Acad Dermatol*. 2002;46:S5–S7.
23. Findlay GH, Morrison JG, Simon IW. Exogenous ochronosis and pigmented colloid milium from hydroquinone bleaching creams. *Br J Dermatol*. 1975;93:613–622.
24. Zeng YP, Ngyen GH, Fang K, Jin HZ. A split-face treatment of adult colloid milium using a non-ablative, 1550-nm, erbium-glass fractional laser. *J Eur Acad Dermatol Venereol*. 2016;30:490–491.
25. Cimaz R, La Torre F. Mucopolysaccharidoses. *Curr Rheumatol Rep*. 2014;16:389.
26. Freeman RG. A pathological basis for the cutaneous papules of mucopolysaccharidosis II (the Hunter syndrome). *J Cutan Pathol*. 1977;4:318–328.
27. Concolino D, Deodato F, Parini R. Enzyme replacement therapy: efficacy and limitations. *Ital J Pediatr*. 2018;44(Suppl 2):120.
28. Taylor M, Khan S, Stapleton M, et al. Hematopoietic stem cell transplantation for mucopolysaccharidoses; past, present, and future. *Biol Blood Marrow Transplant*. 2019;25:e226–e246.
29. Noh H, Lee JL. Current and potential therapeutic strategies for mucopolysaccharidoses. *J Clin Pharm Ther*. 2014;39:215–224.
29a. Gentner B, Tucci F, Galimberti S, et al. Hematopoietic stem- and progenitor-cell gene therapy for Hurler syndrome. *N Engl J Med*. 2021;385:1929–1940.

Downloaded for Anonymous User (n/a) at Egyptian Knowledge Bank from ClinicalKey.com by Elsevier on March 10, 2024. For personal use only. No other uses without permission. Copyright ©2024. Elsevier Inc. All rights reserved.

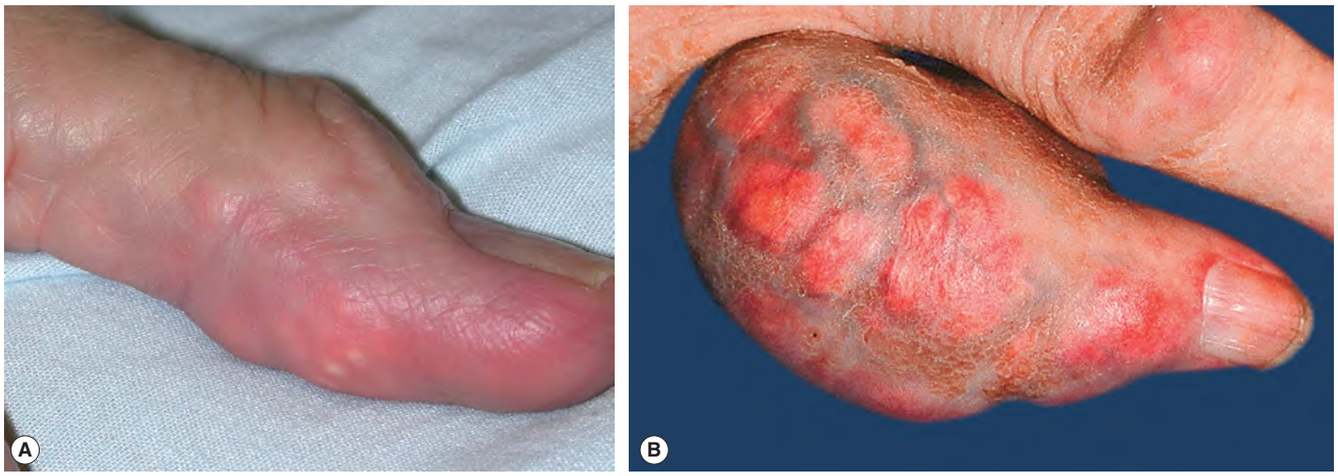

eFig. 48.1 Tophaceous gout. The deposits create a multilobulated appearance and can vary from localized (**A**) to extensive with fusiform swelling (**B**).

eFig. 48.2 Tophaceous gout involving the ear. A Small yellow papule on the helix. **B** Larger yellow nodule on the antihelix. The small yellow–white areas within the nodule represent deposits that can be expressed following a shallow incision, allowing for a bedside diagnosis. *A, Courtesy Jeffrey Cohen, MD; Courtesy Jonathan S. Leventhal, MD*.

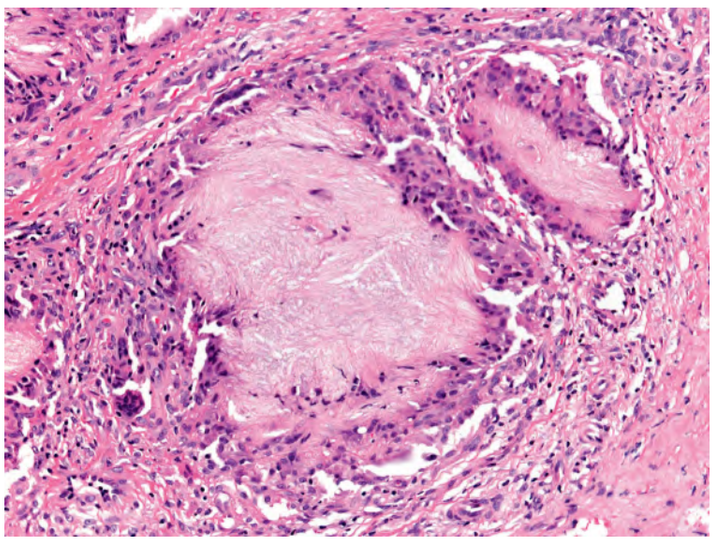

eFig. 48.3 Tophaceous gout – histopathologic features. Deposits of amorphous, acellular material within the dermis. Histiocytes and multinucleated giant cells surround the deposits. *Courtesy Lorenzo Cerroni, MD*.

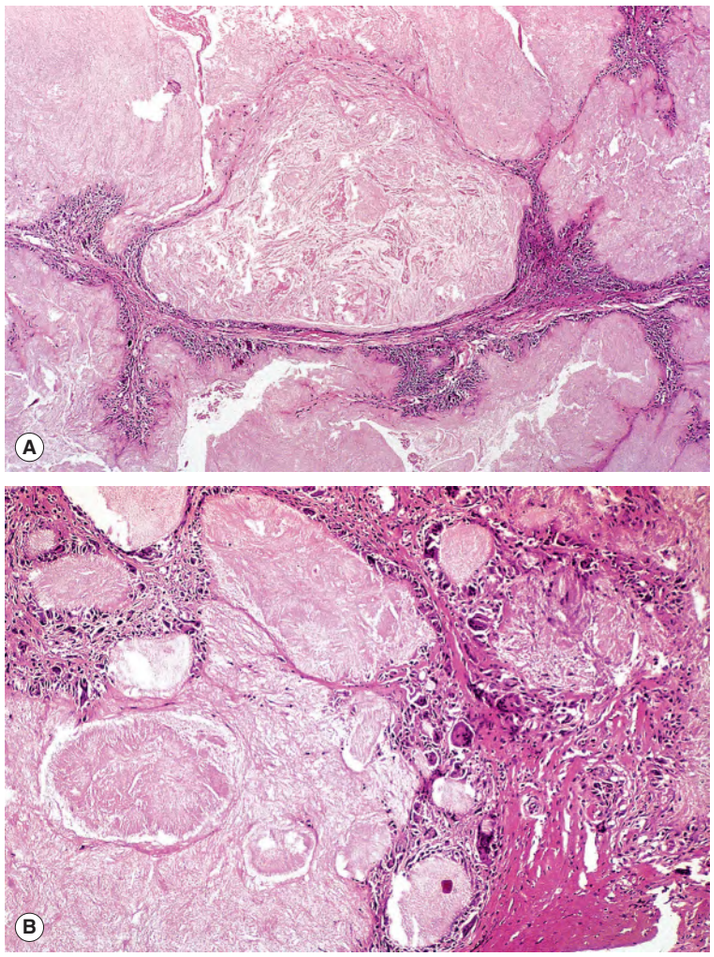

eFig. 48.4 Tophaceous gout – histopathologic features. A Deposits of amorphous, acellular material within the dermis. **B** Higher magnification. Needle-like spaces are present within the amorphous deposits, and histiocytes and multinucleated giant cells surround the deposits.

Downloaded for Anonymous User (n/a) at Egyptian Knowledge Bank from ClinicalKey.com by Elsevier on March 10, 2024. For personal use only. No other uses without permission. Copyright ©2024. Elsevier Inc. All rights reserved.

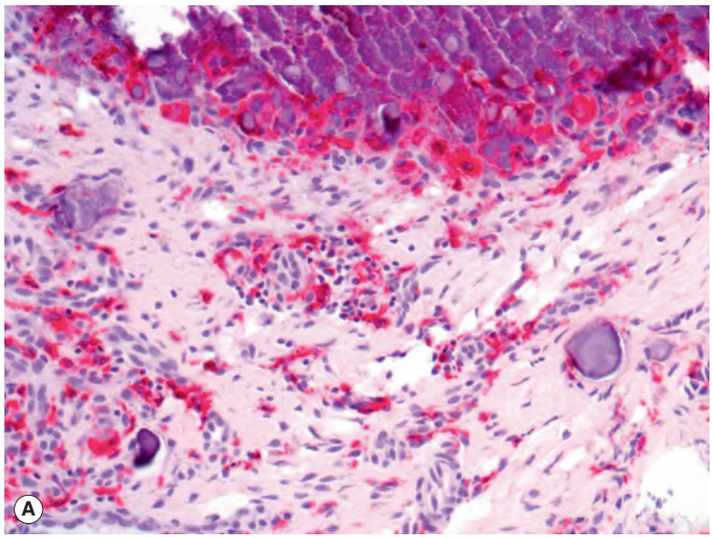

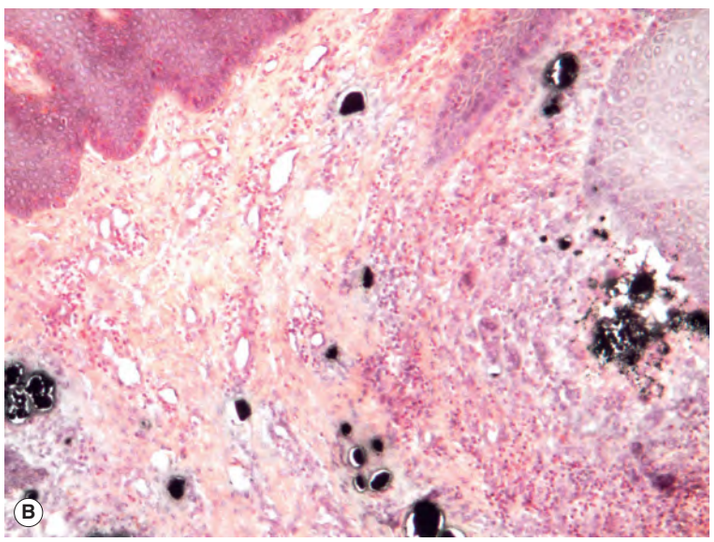

eFig. 48.5 Pseudogout – histopathologic features. A Calcium deposits in the upper dermis as well as rhomboid crystals. **B** Verhoeff–van Gieson staining demonstrates the foci of calcification.

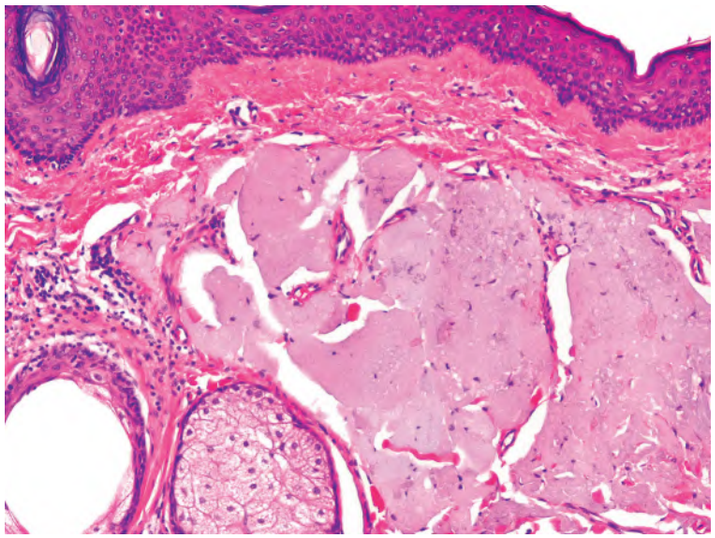

eFig. 48.6 Adult colloid milium – histopathologic features. Nodular mass of homogeneous material within the upper dermis with a subepidermal grenz zone. Note fissures and clefts within the mass as well as scattered fibroblasts. *Courtesy Luis Requena, MD.*

eFig. 48.7 Extensive dermal melanocytosis (Mongolian spots) and hypertrichosis in a 4-month-old girl with Hunter syndrome.

Downloaded for Anonymous User (n/a) at Egyptian Knowledge Bank from ClinicalKey.com by Elsevier on March 10, 2024. For personal use only. No other uses without permission. Copyright ©2024. Elsevier Inc. All rights reserved.